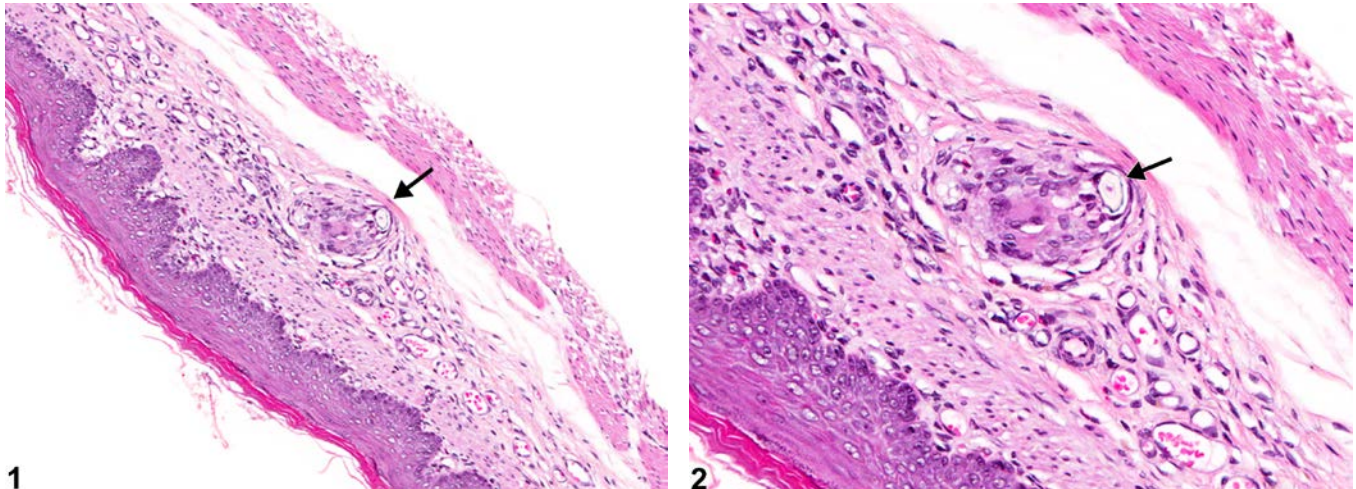




# NTP Nonneoplastic Lesion Atlas

## Stomach, Forestomach – Foreign Body



**Figure Legend:** **Figure 1** Stomach, Forestomach - Foreign body in a male F344/N rat from a chronic study. A foreign body (hair) (arrow) has penetrated the epithelium and submucosa. **Figure 2** Stomach, Forestomach - Foreign body in a male F344/N rat from a chronic study (higher magnification of Figure 1). A foreign body (hair) (arrow) with associated granulomatous inflammation is present in the submucosa.

**Comment:** Hair or feed material can become embedded in the wall of the forestomach secondary to injury from a gavage procedure or ulceration from xenobiotics. In Figure 1 and Figure 2, a small granuloma with a central hair shaft (arrow) is in the submucosa; the overlying mucosa has healed from a previous injury. This is considered a small incidental lesion in a control animal that may have occurred secondary to previous gavage trauma.

**Recommendation:** A primary foreign body should be diagnosed but not graded. If a foreign body causes a significant inflammatory response, then both the foreign body and inflammation are diagnosed. A foreign body such as hairs or feed material that has been passively pushed into an ulcerated area should not be diagnosed separately but can be described in the narrative.

### References:

Brown HR, Hardisty JF. 1990. Oral cavity, esophagus and stomach. In: Pathology of the Fischer Rat (Boorman GA, Montgomery CA, MacKenzie WF, eds). Academic Press, San Diego, CA, 9-30.  
Abstract: <http://www.ncbi.nlm.nih.gov/nlmcatalog/9002563>



# NTP Nonneoplastic Lesion Atlas

## *Stomach, Forestomach – Foreign Body*

Leininger JR, Jokinen MP, Dangler CA, Whiteley LO. 1999. Oral cavity, esophagus, and stomach. In: Pathology of the Mouse (Maronpot RR, ed). Cache River Press, St Louis, MO, 29-48.

Abstract: <http://www.cacheriverpress.com/books/pathmouse.htm>

### **Authors:**

Linda H. Kooistra, DVM, PhD, DACVP  
Pathologist  
Charles River Laboratories, Inc.  
Research Triangle Park, NC

Abraham Nyska, DVM, Diplomate ECVP, Fellow IATP  
Expert in Toxicologic Pathology  
Visiting Full Professor of Pathology  
Sackler School of Medicine, Tel Aviv University  
Timrat Israel