

# NTP Nonneoplastic Lesion Atlas

## *Uterus – Introduction*

Information on the following lesions is available in this section:

Uterus - Adenomyosis

Uterus - Amyloid

Uterus - Atrophy

Uterus, Cervix - Cyst, Squamous

Uterus - Decidual Reaction

Uterus - Dilation

Uterus - Edema

Uterus - Endometrial Stromal Polyp

Uterus, Endometrium - Hyperplasia, Cystic

Uterus, Endometrium - Metaplasia, Squamous

Uterus - Fibrosis

Uterus - Hemorrhage

Uterus - Hyperplasia, Atypical

Uterus - Hyperplasia, Stromal

Uterus - Inflammation

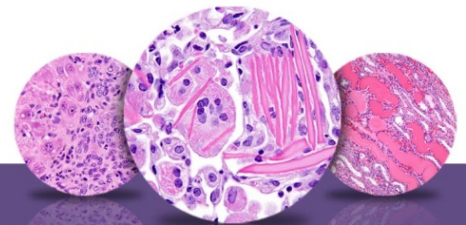
Uterus - Mesonephric Duct Remnant

Uterus - Necrosis

Uterus - Pigment

Uterus - Thrombus

Click the tabs in the left-hand column.



# NTP Nonneoplastic Lesion Atlas

## *Uterus – Introduction*

### **Authors:**

Gabrielle Willson, BVMS, DipRCPath, FRCPath, MRCVS  
Senior Pathologist  
Experimental Pathology Laboratories, Inc.  
Research Triangle Park, NC

Karen Y. Cimon, DVM, MS  
Senior Pathologist  
Experimental Pathology Laboratories, Inc.  
Research Triangle Park, NC