



NTP Nonneoplastic Lesion Atlas

Bone Marrow – Infiltration cellular, mast cell

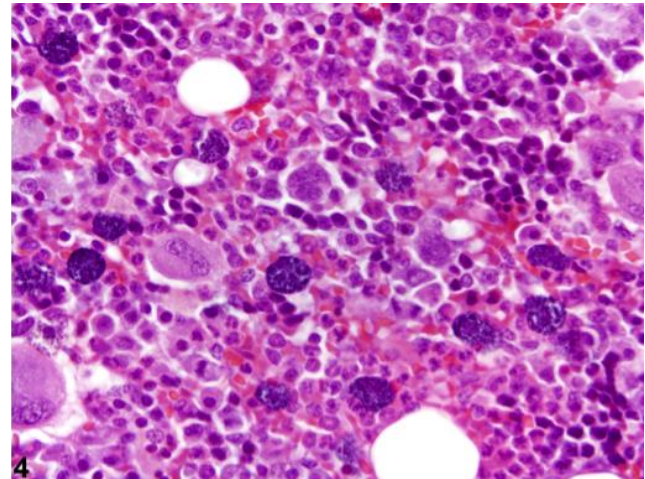
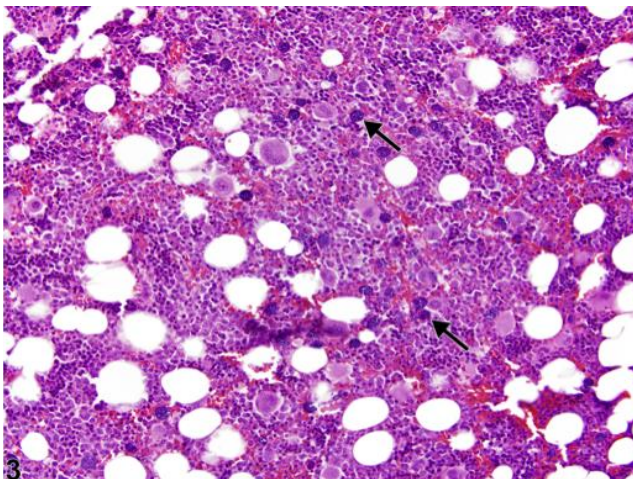
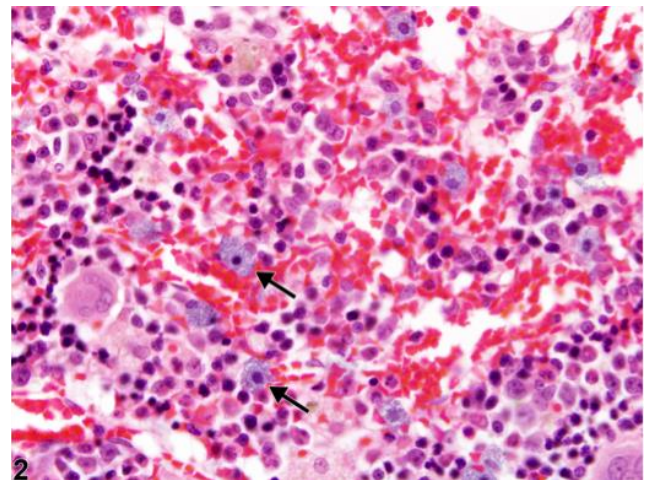
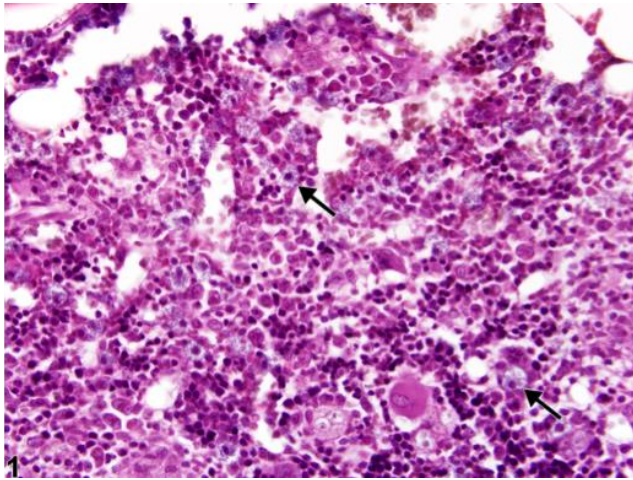
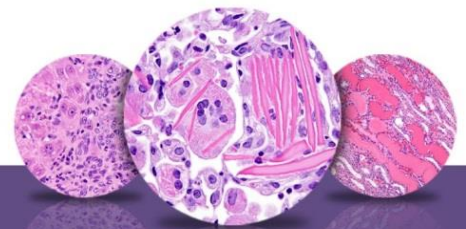


Figure Legend: **Figure 1** Bone marrow in a female F344/N rat from a chronic study showing increased mast cells (arrows). **Figure 2** Bone marrow in a female F344/N rat from a chronic study showing increased mast cells (arrows). **Figure 3** Bone marrow in a male F344/N rat from a chronic study. Stained with Giemsa, increased numbers of mast cells (arrows) are easily identified by their purple cytoplasmic granules. **Figure 4** Bone marrow in a male F344/N rat from a chronic study (higher magnification of Figure 3). Mast cells are easily identified by their purple cytoplasmic granules.



NTP Nonneoplastic Lesion Atlas

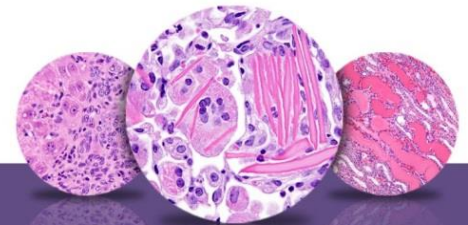
Bone Marrow – Infiltration cellular, mast cell

Comment: Mast cell infiltration is a reactive change defined as increased numbers of loosely scattered, morphologically normal mast cells compared with concurrent controls. In rats, mast cells are present in relatively high numbers in the bone marrow, comprising approximately 1-3% of all nucleated bone marrow cells, in contrast to dogs, where they are rarely observed in bone marrow cytology, and humans, where they comprise less than 0.1% of all nucleated bone marrow cells. Less is known about total mast cell numbers in the bone marrow of mice. Typical mast cells are round to oval with a central to slightly eccentric, round nucleus and a pale granular cytoplasm as seen on hematoxylin and eosin–stained histologic slides (Figure 1 and Figure 2). With most Romanowsky-type stains (e.g., Giemsa), mast cells are easily identified by their metachromatic cytoplasmic granules (Figure 3 and Figure 4).

The causes of increased bone marrow mast cells in rodents are not well defined. In humans and dogs, mast cell infiltration is secondary to such conditions as inflammation, parasitism, uremia (renal failure), aplastic anemia, osteoporosis, and hematologic diseases (e.g., preleukemias, lymphoproliferative diseases). The increased mast cells may be accompanied by increases in lymphocytes and plasma cells.

Recommendation: Because of the variability of normal mast cell numbers in rodent bone marrow, comparison with concurrent controls is especially important when a perceived increase in marrow mast cells is observed in treated animals. Increases in numbers of mast cells should always be recorded and given a severity grade.

The term “mastocytosis” should not be used in lieu of the diagnosis of mast cell infiltration. In humans, mastocytosis refers to a heterogeneous group of disorders (most of which have been shown to be clonal and includes the human equivalent of mast cell tumors) characterized by abnormal growth and accumulation of mast cells in one or more organ systems. The diagnosis of a bone marrow mast cell tumor in rodents is appropriate when mast cells are found in multifocal or diffuse, dense compact clusters or sheets. However, the presence of increased numbers of loosely scattered mast cells in and of itself warrants a diagnosis of infiltration, unless



NTP Nonneoplastic Lesion Atlas

Bone Marrow – Infiltration cellular, mast cell

other criteria (e.g., atypical morphology, mast cell tumor in another location) are indicative of neoplasia.

References:

Bain BJ, Clark DM, Lampert IA, Wilkins BS. 2001. Bone Marrow Pathology, 3rd ed. Blackwell, Ames, IA, 90–140.

Abstract: <http://www.ncbi.nlm.nih.gov/pubmed/13207787>

Bookbinder PF, Butt MT, Harvey HJ. 1992. Determination of the number of mast-cells in lymph-node, bone-marrow, and buffy coat cytological specimens from dogs. *J Am Vet Med Assoc* 200:1648–1650.

Abstract: <http://www.ncbi.nlm.nih.gov/pubmed/1624339>

Escribano L, Orfao A, Villarrubia J, Díaz-Agustín B, Cerveró C, Rios A, Velasco JL, Ciudad J, Navarro JL, San Miguel JF. 1998. Immunophenotypic characterization of human bone marrow mast cells. A flow cytometric study of normal and pathologic bone marrow samples. *Am Cell Pathol* 16:151–159.

Abstract: <http://www.ncbi.nlm.nih.gov/pubmed/9699944>

Horny H-P, Sotlar K, Valent P. 2011. Mastocytosis. In: *Hematopathology* (Jaffe ES, Harris NL, Vardiman JW, Campo E, Arber DA, eds). Elsevier Saunders, St Louis, 757–776.

Abstract:

<http://www.us.elsevierhealth.com/Medicine/Pathology/book/9780721600406/Hematopathology/>

Jamur MC, Grodzki AG, Morena AN, de Mello LF, Pastor MV, Berenstein EH, Siraganian RP, Oliver C. 2001. Identification and isolation of rat bone marrow-derived mast cells using mast cell-specific monoclonal antibody AA4. *J Histochem Cytochem* 49:219–228.

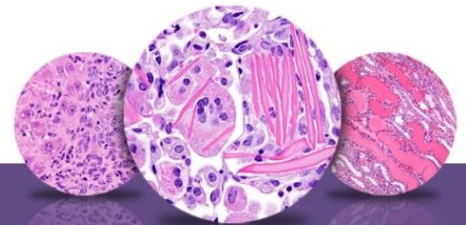
Abstract: <http://www.ncbi.nlm.nih.gov/pubmed/11156690>

Krokowski M, Sotlar K, Krauth M-T, Födinger M, Valent P, Horny H-P. 2005. Delineation of patterns of bone marrow mast cell infiltration in systemic mastocytosis: Value of CD25, correlation with subvariations of the disease and separation from mast cell hyperplasia. *Am J Clin Pathol* 124:560–568.

Abstract: <http://www.ncbi.nlm.nih.gov/pubmed/16146815>

Provencher-Bolliger A. 2004. Cytological evaluation of bone marrow in rats: Indications, methods and normal morphology. *Vet Clin Pathol* 33:58–67.

Abstract: <http://www.ncbi.nlm.nih.gov/pubmed/15195264>



NTP Nonneoplastic Lesion Atlas

Bone Marrow – Infiltration cellular, mast cell

References:

Valant P, Horny H-P, Escibano L, Longley BJ, Li CY, Schwartz LB, Marone G, Nuñez R, Akin C, Sotlar K, Sperr WR, Wolff K, Brunning RD, Parwaresch RM, Austen KF, Lennert K, Metcalfe DD, Vardiman JW, Bennett JM. 2001. Diagnostic criteria and classification of mastocytosis: A consensus proposal. *Leuk Res* 25:603–625.

Abstract: <http://www.ncbi.nlm.nih.gov/pubmed/11377686>

Walker D, Cowell RL, Clinkenbeard KD, Feder B, Meinkoth JH. 1997. Bone marrow mast cell hyperplasia in dogs with aplastic anemia. *Vet Clin Pathol* 26:106–111.

Abstract: <http://onlinelibrary.wiley.com/doi/10.1111/j.1939-165X.1997.tb00719.x/abstract>

Authors:

Michelle C. Cora, DVM, DACVP
Veterinary Medical Officer
NTP Clinical Pathologist
NTP Clinical Pathology Group
National Institute of Environmental Health Sciences
Research Triangle Park, NC

Gregory Travlos, DVM, DACVP
Group Leader, Clinical Pathology Group
Cellular and Molecular Pathology Branch
National Institute of Environmental Health Sciences
Research Triangle Park, NC