

NTP Nonneoplastic Lesion Atlas

Liver, Kupffer cell – Hyperplasia

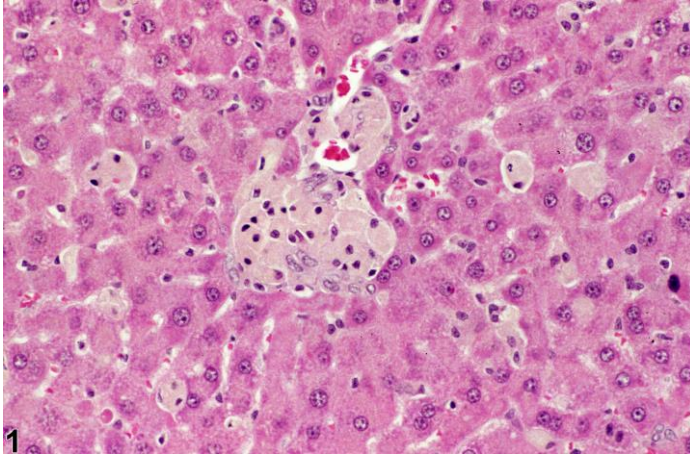
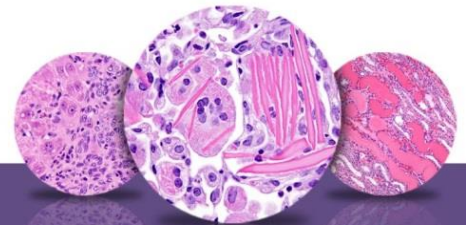


Figure Legend: **Figure 1** Kupffer cell hyperplasia in a female F344/N rat from a 90-day study.

Comment: Kupffer cell hypertrophy and hyperplasia usually occur together and can be seen following uptake of foreign material, test agent, or metabolite, any of which may impart a pigment to the cytoplasm. Kupffer hyperplasia and hypertrophy may also occur in inflammatory conditions. The enlarged Kupffer cells may form sheets or small nodules.

Recommendation: This tissue change is rare in untreated rodents and should be diagnosed and graded whenever present. A description of the morphologic features and tissue distribution should be detailed in the pathology narrative. Because hypertrophy is a consequence of the phagocytic activity of these cells, a separate diagnosis of hypertrophy is generally not necessary. If pigmentation is prominent, a separate diagnosis of pigmentation, along with a qualitative grading of severity, may be appropriate.



NTP Nonneoplastic Lesion Atlas

Liver, Kupffer cell – Hyperplasia

References:

Harada T, Enomoto A, Boorman GA, Maronpot RR. 1999. Liver and gallbladder. In: Pathology of the Mouse: Reference and Atlas (Maronpot RR, Boorman GA, Gaul BW, eds). Cache River Press, Vienna, IL, 119–183.

Abstract: <http://www.cacheriverpress.com/books/pathmouse.htm>

National Toxicology Program. 1994. NTP TR-435. Toxicology and Carcinogenesis Studies of 4,4'-Thiobis(6-t-butyl-m-cresol) (CAS No. 96-69-5) in F344/N Rats and B6C3F₁ Mice (Feed Studies). NTP, Research Triangle Park, NC.

Full-Text: http://ntp.niehs.nih.gov/ntp/htdocs/LT_rpts/tr435.pdf

Thoolen B, Maronpot RR, Harada T, Nyska A, Rousseaux C, Nolte T, Malarkey D, Kaufmann W, Kutter K, Deschl U, Nakae D, Gregson R, Winlove M, Brix A, Singl B, Belpoggi F, Ward JM. 2010. Hepatobiliary lesion nomenclature and diagnostic criteria for lesions in rats and mice (INHAND). *Toxicol Pathol* 38:5S–81S.

Full-Text: http://tpx.sagepub.com/content/38/7_suppl/5S.full

Author:

Robert R. Maronpot, DVM, MS, MPH, DACVP, DABT, FIATP
Senior Pathologist
Experimental Pathology Laboratories, Inc.
Research Triangle Park, NC