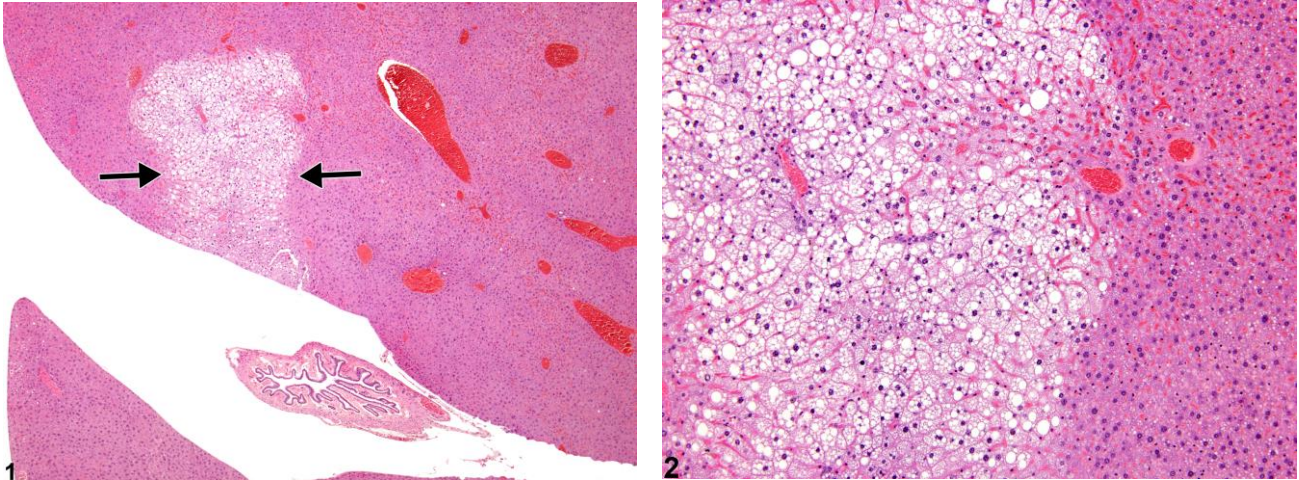


# NTP Nonneoplastic Lesion Atlas

## Liver – Tension lipidosis



**Figure Legend:** **Figure 1** Tension lipidosis in a male B6C3F1 mouse from a chronic study.

**Figure 2** Tension lipidosis in a male B6C3F1 mouse from a chronic study.

**Comment:** Tension lipidosis (Figure 1, arrows) is a focal cytoplasmic vacuolization that occurs near the gallbladder and the attachment of the falciform ligament in mice. This is not considered a pathologic entity but should be distinguished from other forms of cytoplasmic vacuolation. Theoretically, it could be seen at any age. The falciform ligament is a remnant of the ventral mesentery of the fetus that extends from the diaphragmatic area near the liver hilus to the ventral abdominal wall. Tension lipidosis is typically seen just below the parietal surface of the median lobe.

**Recommendation:** Observation of this lesion is dependent on tissue sampling and plane of section and will not necessarily be seen in all animals. Documentation as tension lipidosis is encouraged to avoid confusion with other focal changes in hepatic parenchyma. The pathology narrative should mention that it is a change without pathologic significance.

**Author:**

Robert R. Maronpot, DVM, MS, MPH, DACVP, DABT, FIATP  
Senior Pathologist  
Experimental Pathology Laboratories, Inc.  
Research Triangle Park, NC