



NTP Nonneoplastic Lesion Atlas

Lymph Node – Apoptosis, Lymphocyte

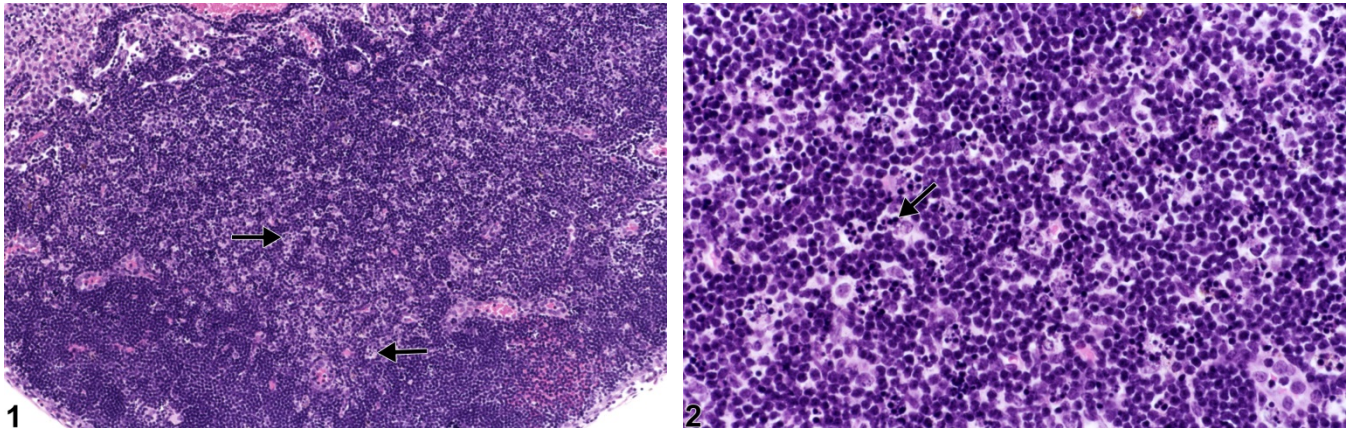


Figure Legend: **Figure 1** Lymph node - Apoptosis, Lymphocyte in a female B6C3F1/N mouse from a subchronic study. Scattered throughout the paracortex are numerous tingible-body macrophages (arrows). **Figure 2** Lymph node - Apoptosis, Lymphocyte in a female B6C3F1/N mouse from a subchronic study (higher magnification of Figure 1). Tingible-body macrophages contain fragments of apoptotic lymphocytes (apoptotic bodies) (arrow).

Comment: Lymphocyte apoptosis is characterized by cell shrinkage, nuclear pyknosis, and fragmentation of lymphocytes into membrane-bound (apoptotic) bodies that are subsequently phagocytized by macrophages (tingible-body macrophages) (Figure 1 and Figure 2, arrowheads). This type of cell death normally occurs in B cells within the germinal centers of secondary follicles, where it is an important homeostatic mechanism. Figure 1 and Figure 2 demonstrate the lesion in T cells in the paracortex. Lymphocyte apoptosis may be normal in lymph nodes, increased in nodes of immunodeficient mice, or induced by various injurious stimuli. Some injurious stimuli induce lymphocyte apoptosis at low doses, whereas at higher doses the stimulus leads to necrosis. Examples of such stimuli include heat, irradiation, hypoxia, and cytotoxic cancer drugs (e.g., cyclophosphamide). Dexamethasone can also incite lymphocyte apoptosis; however, the thymus and spleen are more sensitive to this effect than is the lymph node. If severe enough, lymphocyte apoptosis may lead to lymph node atrophy. Historically, lymphocyte apoptosis has been called “lymphocyte necrosis,” but the correct terminology for this lesion is “lymphocyte apoptosis.” Single-cell necrosis of lymphocytes has not previously been described in the lymph node. Lymphocyte apoptosis must be differentiated from necrosis, although both can occur together. Necrosis generally occurs in groups of cells and is



NTP Nonneoplastic Lesion Atlas

Lymph Node – Apoptosis, Lymphocyte

characterized by cell swelling, condensation, fragmentation and dissolution of the nucleus, cell lysis, and accumulation of eosinophilic cytoplasmic and karyorrhectic nuclear debris. Inflammation generally accompanies necrosis because cell lysis releases cellular contents, including proinflammatory mediators, into the interstitial space.

Recommendation: Lymphocyte apoptosis in the lymph node can be normal. If increased compared with concurrent controls, lymphocyte apoptosis should be diagnosed and assigned a severity grade.

References:

Elmore SA. 2006. Enhanced histopathology of the lymph nodes. *Toxicol Pathol* 34:634-647.
Full Text: <http://www.ncbi.nlm.nih.gov/pmc/articles/PMC1783683/>

Elmore SA. 2006. Histopathology of the lymph nodes. *Toxicol Pathol* 34:425-454.
Full Text: <http://www.ncbi.nlm.nih.gov/pmc/articles/PMC1892634/>

Frith CH, Ward JM, Chandra M, Losco PE. Non-proliferative lesions of the hematopoietic system in rats. In: *Guides for Toxicologic Pathology*. STP/ARP/AFIP, Washington, DC.
Abstract: <https://www.toxpath.org/ssdnc/HematopoieticNonprolifRat.pdf>

National Toxicology Program. 2011. NTP TR-536. Toxicology and Carcinogenesis Studies of Bis(2-chloroethoxy)methane (CAS No. 111-91-1) in Rats and B6C3F1 Mice (Dermal Studies). NTP, Research Triangle Park, NC.
Abstract: <http://ntp.niehs.nih.gov/go/34791>

Authors:

Kristen Hobbie, DVM, PhD
Principal Pathologist
Huntingdon Life Sciences
Peterborough, UK

Susan A. Elmore, MS, DVM, DACVP, DABT, FIATP
Staff Scientist, NTP Pathologist
NTP Pathology Group
National Toxicology Program
National Institute of Environmental Health Sciences
Research Triangle Park, NC



National Toxicology Program
U.S. Department of Health and Human Services



NTP Nonneoplastic Lesion Atlas

Lymph Node – Apoptosis, Lymphocyte

Authors:

Holly M. Kolenda-Roberts, DVM, PhD, DACVP
Veterinary Pathologist
SNBL USA
Everett, WA