



NTP Nonneoplastic Lesion Atlas

Lymph Node – Lymphatic Sinus, Ectasia

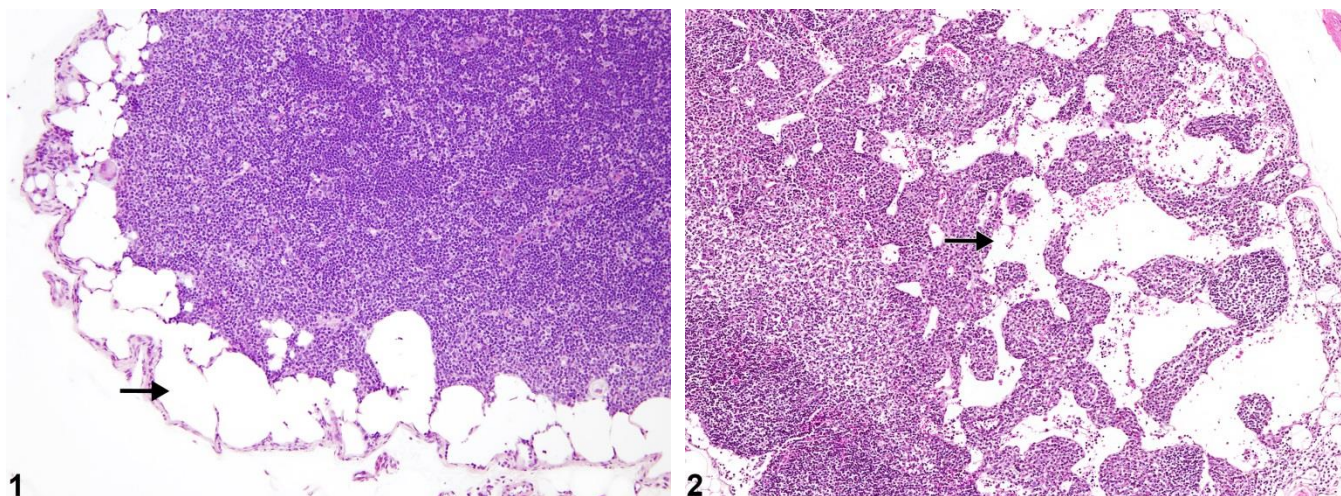
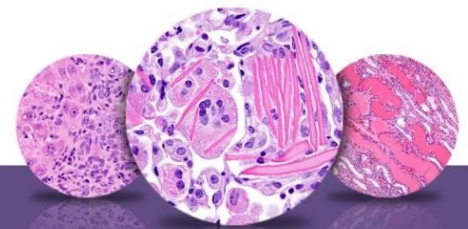


Figure Legend: **Figure 1** Lymph node - Lymphatic sinus, Ectasia in a treated female F344/N rat from a subchronic study. Subcapsular sinuses are ectatic (arrow). **Figure 2** Lymph node - Lymphatic sinus, Ectasia in a treated female B6C3F1/N mouse from a chronic study. Medullary sinuses are ectatic (arrow).

Comment: Lymphatic sinus ectasia can involve the subcapsular (Figure 1, arrow), paracortical, or medullary (Figure 2, arrow) sinuses of lymph nodes in rats and mice. Sinuses are enlarged relative to the size of the lymph node, are lined by lymphatic endothelium, and may be filled with pale eosinophilic/amphophilic material (presumably lymph). Few intraluminal lymphocytes, macrophages, and/or erythrocytes may be present. Lymphatic sinus ectasia may be related to treatment or dose; however, this lesion can also be seen in control and aging rodents, particularly in the mesenteric or mediastinal lymph nodes. Diffuse sinus ectasia may also be associated with lymphoid atrophy. Lymphatic sinus ectasia should be differentiated from blood vessel angiectasis in the lymph node, which is characterized by the dilatation and congestion of thin veins within the cortex, medulla, capsule, hilus, or surrounding connective tissue. Previous terms for lymphatic sinus ectasia are “lymphangiectasia,” “lymphatic cysts,” “cystic lymphatic ectasia,” and “sinus dilatation.”

Recommendation: Lymphatic sinus ectasia should be diagnosed and assigned a severity grade. If this lesion is present as a component of lymphoid atrophy, atrophy should be diagnosed, and the lymphatic sinus ectasia and any other associated lesions should be described in the narrative.



NTP Nonneoplastic Lesion Atlas

Lymph Node – Lymphatic Sinus, Ectasia

References:

Elmore SA. 2006. Histopathology of the lymph nodes. *Toxicol Pathol* 34:425-454.
Full Text: <http://www.ncbi.nlm.nih.gov/pmc/articles/PMC1892634/>

National Toxicology Program. 2004. Short-Term Bioassay of Indole-3-Carbinol (CAS No. 700-06-1) in F344/N Rats and B6C3F1 Mice (Gavage Studies). NTP, Research Triangle Park, NC.

National Toxicology Program. 2007. NTP TR-538. Toxicology and Carcinogenesis Studies of Methyl Isobutyl Ketone (CAS No. 108-10-1) in F344/N Rats and B6C3F1 Mice (Inhalation Studies). NTP, Research Triangle Park, NC.
Abstract: <http://ntp.niehs.nih.gov/go/17630>

Stefanski SA, Elwell MR, Stromberg PC. 1990. Spleen, lymph nodes, and thymus. In: *Pathology of the Fischer Rat: Reference and Atlas* (Boorman GA, Eustis SL, Elwell MR, Montgomery CA, MacKenzie WF, eds). Academic Press, San Diego, 369-394.

Ward JM, Mann PC, Morishima H, Frith CH. 1999. Thymus, spleen, and lymph nodes. In: *Pathology of the Mouse* (Maronpot RR, ed). Cache River Press, Vienna, IL, 333-360.

Authors:

Kristen Hobbie, DVM, PhD
Principal Pathologist
Huntingdon Life Sciences
Peterborough, UK

Susan A. Elmore, MS, DVM, DACVP, DABT, FIATP
Staff Scientist, NTP Pathologist
NTP Pathology Group
National Toxicology Program
National Institute of Environmental Health Sciences
Research Triangle Park, NC

Holly M. Kolenda-Roberts, DVM, PhD, DACVP
Veterinary Pathologist
SNBL USA
Everett, WA