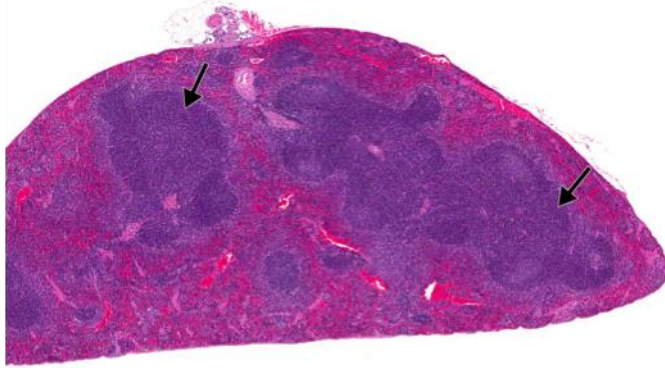
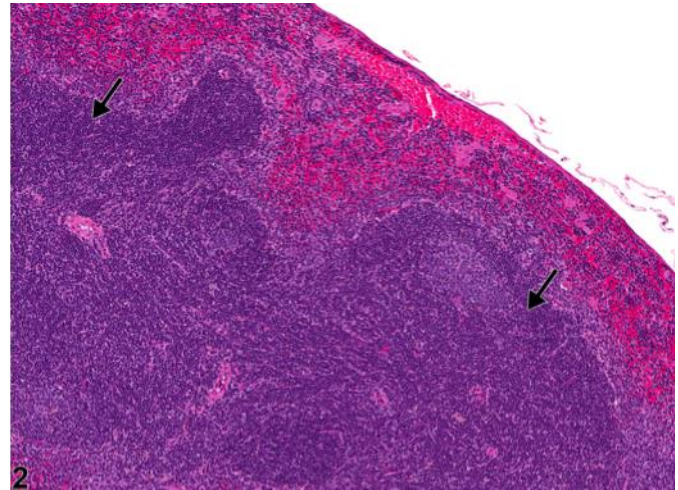


# NTP Nonneoplastic Lesion Atlas

## *Spleen – Hyperplasia, Lymphocyte*



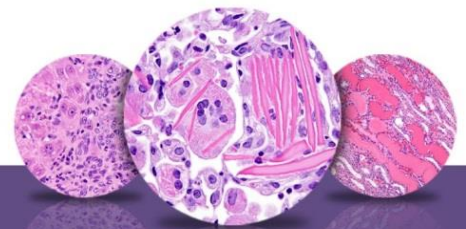
1



2

**Figure Legend:** **Figure 1** Spleen - Hyperplasia, Lymphocyte in a male B6C3F1/N mouse from a chronic study. The splenic white pulp is expanded by increased numbers of normal lymphocytes (arrows). **Figure 2** Spleen - Hyperplasia, Lymphocyte in a male B6C3F1/N mouse from a chronic study (higher magnification of Figure 1). Lymphocyte hyperplasia is present in the periarteriolar lymphoid sheaths (arrows).

**Comment:** Lymphocyte hyperplasia of the spleen is an increase in the number of lymphocytes outside the range of normal compared with concurrent controls. The result can be variable increases in the area and number of white pulp elements (periarteriolar lymphoid sheaths [PALS], follicles, and/or marginal zones) (Figure 1 and Figure 2, arrows). This lesion can be focal or generalized. Lymphocyte hyperplasia in the spleen occurs more frequently in mice than in rats, and female mice are more commonly affected than male mice. Marked lymphocyte hyperplasia can be difficult to distinguish from early lymphoma of the spleen; however, the splenic architecture (white pulp and red pulp compartments) should be maintained with lymphocyte hyperplasia (Figure 1 and Figure 2), whereas loss of the splenic architecture would be expected with lymphoma. With generalized lymphocyte hyperplasia, there can be confluency of the PALS regions (Figure 1), so cellular morphology should be evaluated to differentiate from lymphoma. Lymphoma consists of monomorphic (or pleomorphic) neoplastic lymphocytes with increased cellular atypia, whereas lymphocyte hyperplasia consists of increased numbers of normal, mature lymphocytes.



# NTP Nonneoplastic Lesion Atlas

## *Spleen – Hyperplasia, Lymphocyte*

**Recommendation:** Whenever present, lymphocyte hyperplasia of the spleen should be diagnosed and assigned a severity grade. The number of lymphocytes in the spleen is often variable; therefore, the pathologist must carefully examine and determine the range of normal for a study by comparing with concurrent controls. The plane of section should also be taken into consideration (transverse, longitudinal, tangential, or shallow sections) when evaluating the spleen. Diagnosis should be based upon the pathologist's best judgment.

### **References:**

Elmore SA. 2006. Enhanced histopathology of the spleen. *Toxicol Pathol* 34:648-655.  
Full Text: <http://www.ncbi.nlm.nih.gov/pmc/articles/PMC1828535/>

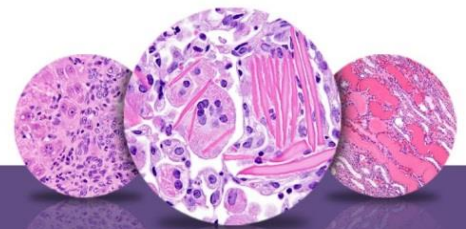
National Toxicology Program. 2011. NTP TR-570. Toxicology and Carcinogenesis Studies of  $\alpha,\beta$ -Thujone (CAS No. 76231-76-0) in F344/N Rats and B6C3F1 Mice (Gavage Studies). NTP, Research Triangle Park, NC.  
Abstract: <http://ntp.niehs.nih.gov/go/36137>

Stefanski SA, Elwell MR, Stromberg PC. 1990. Spleen, lymph nodes, and thymus. In: *Pathology of the Fischer Rat: Reference and Atlas* (Boorman GA, Eustis SL, Elwell MR, Montgomery CA, MacKenzie WF, eds). Academic Press, San Diego, 369-394.

Suttie AW. 2006. Histopathology of the spleen. *Toxicol Pathol* 34:466-503.  
Full Text: <http://tpx.sagepub.com/content/34/5/466.full.pdf>

Ward JM, Mann PC, Morishima H, Frith CH. 1999. Thymus, spleen, and lymph nodes. In: *Pathology of the Mouse* (Maronpot RR, ed). Cache River Press, Vienna, IL, 333-360.

Ward JM, Rehg JE, Morse HC III. 2012. Differentiation of rodent immune and hematopoietic system reactive lesions from neoplasias. *Toxicol Pathol* 40:425-434.  
Abstract: <http://www.ncbi.nlm.nih.gov/pubmed/22215512>



# NTP Nonneoplastic Lesion Atlas

## *Spleen – Hyperplasia, Lymphocyte*

### **Authors:**

Kristen Hobbie, DVM, PhD  
Principal Pathologist  
Huntingdon Life Sciences  
Peterborough, UK

Susan A. Elmore, MS, DVM, DACVP, DABT, FIATP  
Staff Scientist, NTP Pathologist  
NTP Pathology Group  
National Toxicology Program  
National Institute of Environmental Health Sciences  
Research Triangle Park, NC

Holly M. Kolenda-Roberts, DVM, PhD, DACVP  
Veterinary Pathologist  
SNBL USA  
Everett, WA