



NTP Nonneoplastic Lesion Atlas

Preputial gland – Mineralization

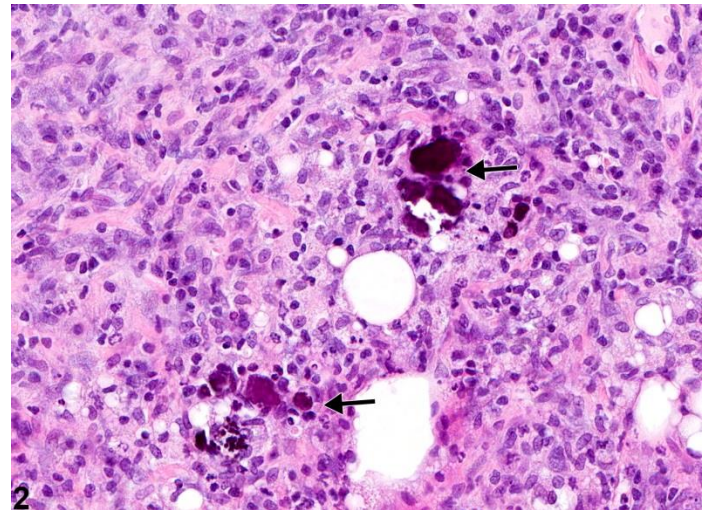
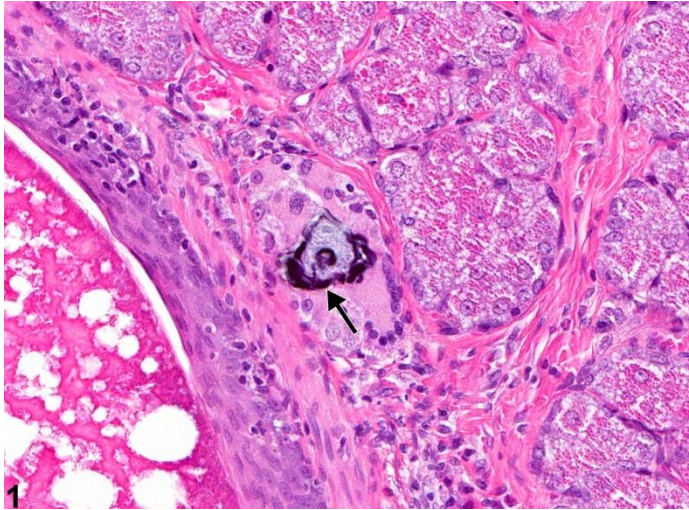
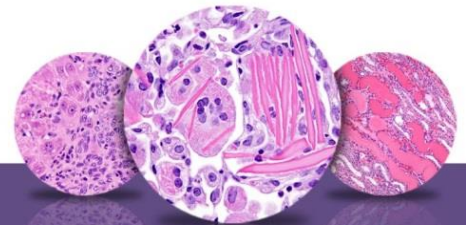


Figure Legend: **Figure 1** Preputial Gland - Mineralization. Arrow indicates mineral deposits in a male F344/N rat from a subchronic study. **Figure 2** Preputial Gland - Mineralization. Arrows indicate mineral deposits in a male F344/N rat from a subchronic study.

Comments: Mineralization consists of deposition of irregular amorphous basophilic material (arrows, Figure 1 and Figure 2). Two types of mineralization may occur: metastatic (calcification of normal tissue associated with high blood levels of calcium) or dystrophic (mineral deposits in abnormal or degenerating tissue not associated with increased blood levels of calcium). When systemic, metastatic mineralization can be present in multiple organs. Mineralization can be focal or multifocal. Mineralization in the preputial gland is unusual and is likely an incidental finding unrelated to chemical treatment. However, it may be associated with inflammation (Figure 2).

Recommendation: Mineralization should be recorded and given a severity grade. If both glands are affected, the diagnosis should be qualified as bilateral and the severity based on the more severely affected gland. If it occurs in multiple tissues as a systemic response, it is not necessary to separately diagnose mineralization in the preputial gland. However, its presence in the preputial gland may be mentioned in the pathology narrative.



NTP Nonneoplastic Lesion Atlas

Preputial gland – Mineralization

References:

Boorman GA, Elwell MR, Mitsumori K. 1990. Male accessory sex glands, penis, and scrotum. In: Pathology of the Fischer Rat: Reference and Atlas (Boorman GA, Eustis SL, Elwell MR, Montgomery CA, MacKenzie WF, eds). Academic Press, San Diego, 419-428.

Abstract: <http://www.ncbi.nlm.nih.gov/nlmcatalog/9002563>

Gordon LR, Majka JA, Boorman GA. 1996. Spontaneous nonneoplastic and neoplastic lesions and experimentally induced neoplasms of the testes and accessory sex glands. In: Pathobiology of the Aging Mouse, Vol 1 (Mohr U, Dungworth DL, Capen CC, Carlton WW, Sundberg JP, Ward JM, eds). ILSI Press, Washington, DC, 421-441.

Abstract: <http://catalog.hathitrust.org/Record/008994685>

Haines DC, Eustis SL. 1990. Specialized sebaceous glands. In: Pathology of the Fischer Rat: Reference and Atlas (Boorman GA, Eustis SL, Elwell MR, Montgomery CA, MacKenzie WF, eds). Academic Press, San Diego, 279-293.

Abstract: <http://www.ncbi.nlm.nih.gov/nlmcatalog/9002563>

Rudmann D, Cardiff R, Chouinard L, Goodman D, Kuttler K, Marxfeld H, Molinolo A, Treumann S, Yoshizawa K. 2012. Proliferative and nonproliferative lesions of the rat and mouse mammary, Zymbal's, preputial, and clitoral glands. Toxicol Pathol 40:7S-39S.

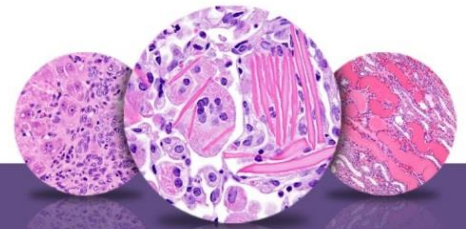
Abstract: <http://www.ncbi.nlm.nih.gov/pubmed/22949413>

Authors:

Dianne M. Creasy, PhD, Dip RCPATH, FRCPath
Dianne Creasy Consulting LLC
Pipersville, PA

Robert R. Maronpot, DVM, MS, MPH, DACVP, DABT, FIATP
Senior Pathologist
Experimental Pathology Laboratories, Inc.
Research Triangle Park, NC

Gordon Flake, MD
Staff Scientist
NTP Pathologist
Cellular and Molecular Pathology Branch
National Institute of Environmental Health Sciences
Research Triangle Park, NC



NTP Nonneoplastic Lesion Atlas

Preputial gland – Mineralization

Authors:

Dipak K. Giri, DVM, PhD, DACVP
Toxicologic Pathologist
Integrated Laboratory Systems, Inc.
Research Triangle Park, NC