

NTP Nonneoplastic Lesion Atlas

Brain, Leptomeninges – Hamartoma, lipomatous

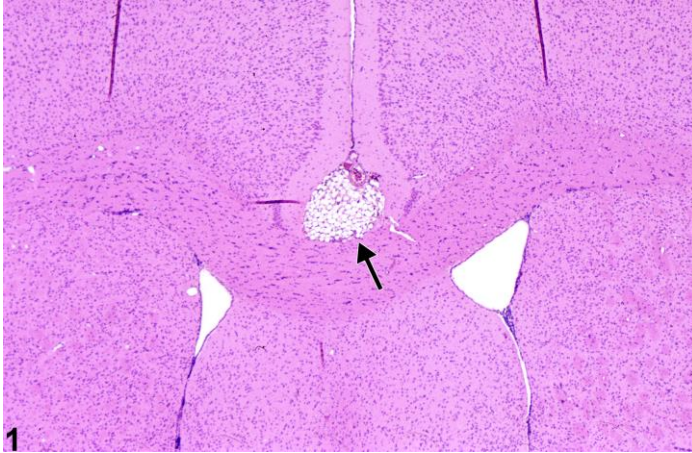


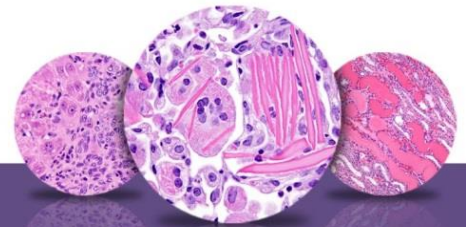
Figure Legend: Figure 1 Leptomeningeal lipomatous hamartoma in an untreated male B6C3F1 mouse from a chronic study. The arrow identifies the location of the lipomatous mass.

Comment: Figure 1 depicts a neurodevelopmental anomaly. This midline leptomeningeal lipomatous hamartoma is located at the base of the cingulate gyrus, immediately above the corpus callosum and septal nuclei. Consisting of normal white adipocytes, it is in the common location for a lipomatous hamartoma. The expansion of the hamartoma has had little compressive effect on adjacent structures and was not accompanied by noticeable clinical neurological signs. This type of hamartoma is uncommon in rodent studies. It is not to be confused with a lipoma or liposarcoma.

Recommendation: Lipomatous hamartomas should be diagnosed in NTP studies and the subsite specified.

References:

Krinke GJ, Kaufmann W, Mahrous AT, Schaetti P. 2000. Morphologic characterization of spontaneous nervous system tumors in mice and rats. *Toxicol Pathol* 28:178–192.
Abstract: <http://www.ncbi.nlm.nih.gov/pubmed/10669006>



NTP Nonneoplastic Lesion Atlas

Brain, Leptomeninges – Hamartoma, lipomatous

Authors:

Peter Little, DVM, MS, PhD, DACVP
Neuropathology Consultant
Experimental Pathology Laboratories, Inc.
Research Triangle Park, NC

Deepa B. Rao, BVSc, MS, PhD, DABT, DACVP
NTP Pathologist (Contractor)
Integrated Laboratory Systems, Inc.
Research Triangle Park, NC