

NTP Nonneoplastic Lesion Atlas

Urinary bladder – Proteinaceous Plug

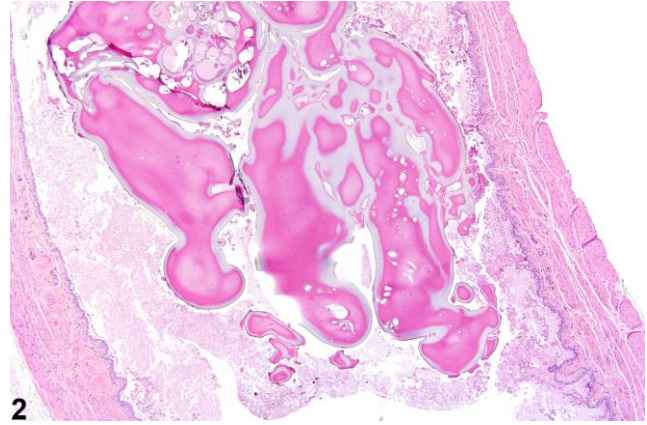
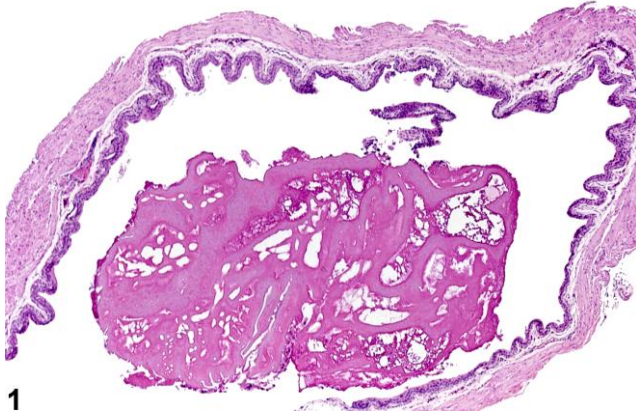
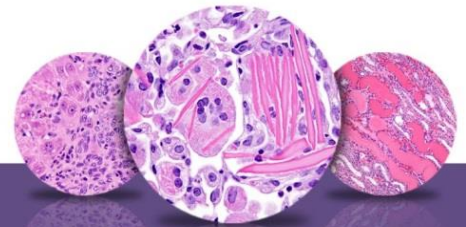


Figure Legend: **Figure 1** An eosinophilic amorphous proteinaceous plug in the bladder lumen from a male B6C3F1 mouse in a chronic study. **Figure 2** A proteinaceous plug associated with other flocculent, eosinophilic material, from a male F344/N rat in an acute study.

Comment: Proteinaceous plugs are commonly noted as a postmortem change resulting from an agonal secretion of accessory sex gland fluids during euthanasia. Proteinaceous plugs vary in size but can be large, filling the urinary bladder (Figure 1 and Figure 2). Microscopically, the plug is composed of a mixture of an amorphous eosinophilic material, sometimes containing desquamated epithelial cells and spermatozoa. Proteinaceous plugs by themselves have no toxicologic importance and are not precursors of calculi. Plugs may be seen with obstructive syndromes associated with bacterial inflammation. They must be differentiated from calculi.

Recommendation: Proteinaceous plugs occurring alone and not associated with any pathologic lesions should be recognized as an artifact and should not be diagnosed. Occasionally, proteinaceous plugs are recognized grossly, and the pathologist should use his or her judgment to correlate the gross lesion to an artifactual proteinaceous plug.



NTP Nonneoplastic Lesion Atlas

Urinary bladder – Proteinaceous Plug

References:

Gaillard ET. 1999. Ureter, urinary bladder and urethra. In: Pathology of the Mouse: Reference and Atlas (Maronpot RR, Boorman GA, Gaul BW, eds). Cache River Press, Vienna, IL, 235–258.

Abstract: <http://www.cacheriverpress.com/books/pathmouse.htm>

Hard GC, Alden CL, Bruner RH, Frith CH, Lewis RM, Owen RA, Krieg K, Durchfeld-Meyer B. 1999. Non-proliferative lesions of the kidney and lower urinary tract in rats. In: Guides for Toxicologic Pathology. STP/ARP/AFIP, Washington, DC, 1–32.

Full-Text: <http://www.toxpath.org/ssdnc/KidneyBladderNonprolifRat.pdf>

Jokinen MP. 1990. Urinary bladder, ureter, and urethra. In: Pathology of the Fischer Rat: Reference and Atlas (Boorman GA, Eustis SL, Elwell MR, Montgomery CA, MacKenzie WF, eds). Academic Press, San Diego, 109–126.

Abstract: <http://www.ncbi.nlm.nih.gov/nlmcatalog/9002563>

Rapp JP. 1962. Terminal formation of urethral plugs in male mice. Proc Soc Exp Biol Med 111:243–245.

Full-Text: <http://ebm.sagepub.com/content/111/2/243.full.pdf>

Authors:

John Curtis Seely, DVM, DACVP
Senior Pathologist
Experimental Pathology Laboratories, Inc.
Research Triangle Park, NC

Abraham Nyska, DVM, Diplomate ECVP, Fellow IATP
Expert in Toxicologic Pathology
Visiting Full Professor of Pathology
Sackler School of Medicine, Tel Aviv University
Timrat Israel